

## Superior Mesenteric Artery: Clinical Case

Gabriel MN<sup>1\*</sup>, Gilberto GFL<sup>2</sup> and Preciado G<sup>2</sup>

<sup>1</sup>Department of Neurology, Hospital Center of the Presidential General Staff, master's in public health, Doctor in administration and Public Policies, Mexico

<sup>2</sup>University of Guadalajara Lamar MD, Social Service, Mexico

### \*Corresponding author:

Gabriel Miranda Nava,  
Neurologist Head of the Neurology Service of the  
Regional Military Specialty Hospital of Guadalajara,  
Jalisco, Mexico,  
E-mail: drgabrielmiranda@hotmail.com

Received: 01 Feb 2021

Accepted: 24 Feb 2021

Published: 06 Mar 2021

### Copyright:

©2021 Gabriel MN et al., This is an open access article distributed under the terms of the Creative Commons Attribution License, which permits unrestricted use, distribution, and build upon your work non-commercially.

### Keywords:

Toxic megacolon; exploratory laparotomy; superior mesenteric artery ischemia.

### Citation:

Gabriel MN. Superior Mesenteric Artery: Clinical Case. *Annals Onco & Cancer Case Rep.* 2021; V1(3): 1-3.

### 1. Abstract

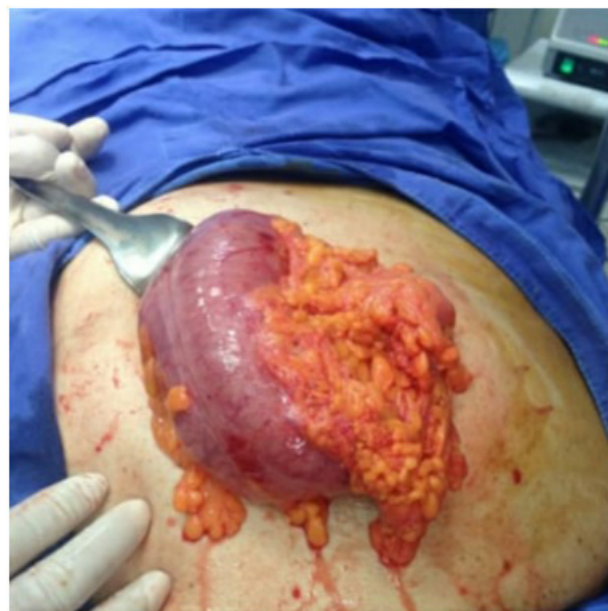Acute mesenteric ischemia refers to a sudden onset of intestinal hypoperfusion, which can be due to a reduction or cessation of arterial inflow leading to cellular damage, intestinal necrosis and eventually death if untreated [1]. The incidence is low, estimated at 0.09-0.2% of all acute surgical admissions [2], this incidence increases with age having a median age of presentation of 70 years old and has a predispose for women at a 3:1 ratio [3]. Prompt diagnostic and innervation are necessary due to increase mortality rates from 50-80%. Mayor risk factors include atrial fibrillation, recent myocardial infarction, cardiac valvopathies, hypertension, atherosclerosis, obesity, and tabaco [4].

### 2. Introduction

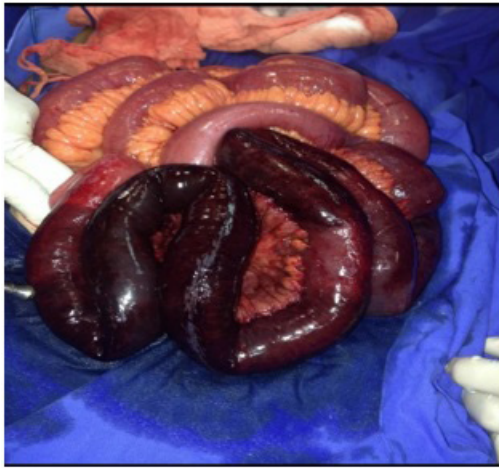The disease was first reported as a case report in 1842 by Carl Von Rokitansky, and in 1927, Willkie further detailed the pathophysiology and diagnostic findings of the disease [5].

The Superior Mesenteric Artery (SMA) is the primary blood supply to the small bowel, the duodenum passes between the aorta and the SMA forming an angle of 35° to 60°, the disease has been associated with the decrease in this angle; [6] however, mayor risk factors include atrial fibrillation, recent myocardial infarction, cardiac valvopathies, hypertension, atherosclerosis, obesity, and tabaco [4]. The diagnosis is difficult due to vague and nonspecific symptoms, however clinical scenario is a patient complaining of excruciating abdominal pain with an unrevealing abdominal exam. Common findings associated have been 44% with nausea, 35%

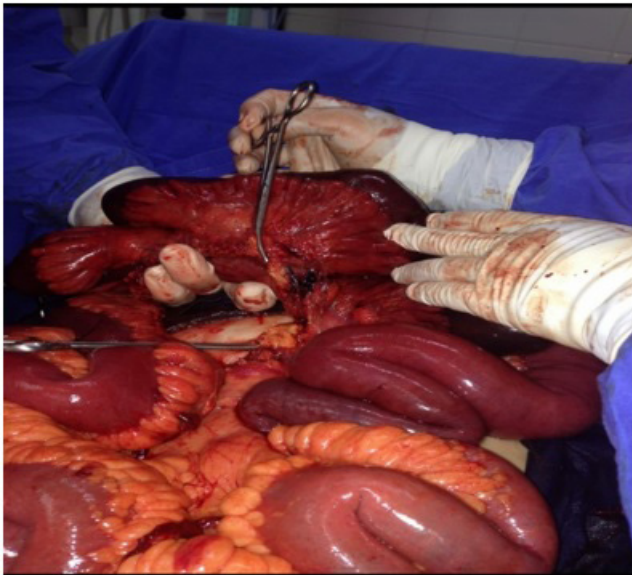
with vomiting, 35% with diarrhea, and 16% with blood per rectum [2, 6]. We report a case of superior mesentery artery ischemia, resulting in a toxic megacolon, who presented with abdominal pain and signs of bowel obstruction.



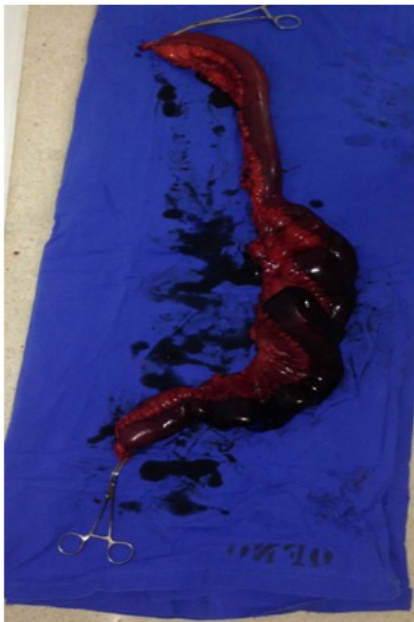**Figure 1:** Toxic megacolon, located on hypogastrium region



**Figure 2:** Necrotic colonic tissue before resection we can observe the colonic wall with necrotic tissue



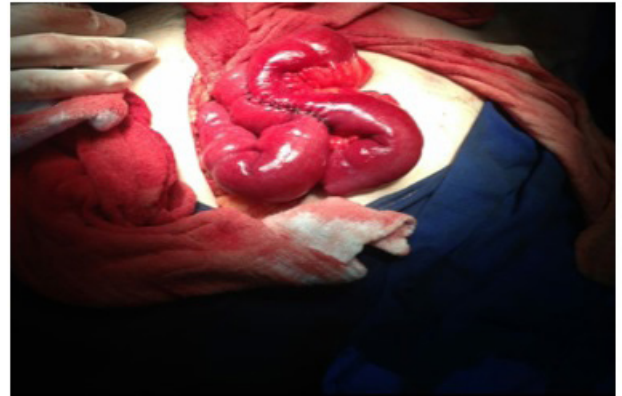**Figure 3:** Site of embolic lesion



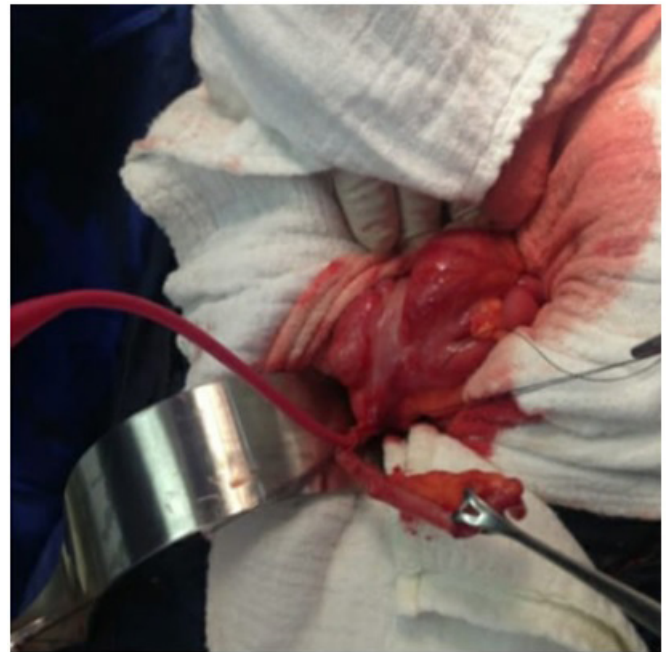**Figure 4:** Resected portion of intestine

### 3. Case Presentation

A 72 year old man presented to office in the San Martin Clinic located in Guadalajara, Mexico with severe abdominal pain that started a few hours ago and irradiated to his back, as well as bloody diarrhea, nausea and vomiting, patient has a history of hypertension, diabetes mellitus since 15 years ago and atrial fibrillation, he is also a heavy smoker since 50 years ago, he didn't drink nor had any other major problem in his personal background, patient is evaluated and is believed to have a toxic megacolon . for which immediate surgery is performed.



**Figure 5:** In this image we can visualize the colon with a laterolateral anastomosis performed on the colonic tissue



**Figure 6:** Cecostomy site

### 4. Findings

Under general anesthesia a toxic megacolon containing a superior mesenteric artery ischemia was found using an exploratory laparotomy.

### 5. Methods

Due to the patients age as well as the size of the colon a surgical

procedure was performed to visualize the size of the lesion, time is important in this type of procedure because of the high mortality it encircles. The goal of the surgery in this case was to achieve 3 scenarios first one was to perform surgery to localize the site of the embolic lesion and revascularize, second goal was to perform a resection of the necrotic tissue and adjacent areas as well as cleaning the area with abundant solutions in order to get rid of all of the necrotic and putrefied colonic tissue in the area in the patients abdominal wall and third goal to perform resection of the necrotic tissue and perform a cecostomy for feeding purposes.

We will describe a patient who came to the emergency department for treatment of acute abdominal pain and bloody diarrhea for which an emergency damage control abdominal surgery is performed under general anesthesia detecting a toxic megacolon furthermore decompression and cecostomy were fulfill. Subsequent localization of the obstruction and the ischemic segment localized succeeding by resection.

An exploratory laparotomy was performed in the beginning of surgery an enlarged and inflamed toxic megacolon was visualize after performing an incision next to the umbilicus in the hypogastrium, the patients colon was then inspected vigorously assessing most of the colon looking to find the site of the superior mesenteric artery and the embolic lesion once it was liberated from the tissue adjacent to it the mesenteric tissue, the superior mesenteric artery is the revascularized and once this is performed we must continue to locate all of the necrotic tissue and perform an incision and posterior resection of the necrotic colonic tissue and the adjacent areas to this tissue, once it is performed closing of the colon was also perform with a laterolateral anastomosis of all of the open wound areas, posterior to this all of the intestinal wall was cleaned vigorously with solutions and antibiotic was given intravenously, posterior to this after anastomosis of the colon was performed then patients appendix was localized then separated from adipose tissue adjacent to it and once it was liberated it was used as a site for feeding posterior to cecostomy.

During the surgical procedure most of the intestinal wall was inspected with the objective to localize all the necrotic regions localized in the colon and perform a cecostomy for feeding purposes as well as localizing the site of where the embolic lesion was localized, first resection of the necrotic tissue was performed.

Once the embolic site was located decompression of the toxic megacolon would be the next step and a cecostomy, the patients appendix site was used for a location for feeding purposes having a direct entry into the colon.

## 6. Discussion

Mesenteric ischemia is mostly of acute origin and in just 10% of cases it is due to a chronic embolism or venous occlusion, it most commonly occurs in patients that have atrial fibrillation and it

mostly occurs due to an embolism that is pump from the left atrium and travel towards the superior mesenteric artery, there are three major parts that can be affected the superior mesenteric artery, the inferior mesenteric artery as well as the celiac region, and it occurs mostly as a severe abdominal pain that can irradiate to the back and is mostly present in males 70 years old and heavy smokers, nausea, vomiting can also be present in this type of condition [1].

## 7. Conclusion

This type of condition is very dangerous and mostly has a poor prognosis but if surgery is performed fast and by an experience medical team the prognosis should improve it is important to take into account the patients age, diet, weight, and chronic illness.

## References:

1. Pearl G, Gilani R. Acute Mesenteric arterial occlusion, UPtodate 2020.
2. Bala M, Kashuk J, Moore EE, Kluger Y. Acute mesenteric ischemia: guidelines of the world society of Emergency surgery, World Journal of Emergency Surgery. 2017; 12: 38.
3. Guerrero SV. Acute mesenteric ischemia, Revista Médica Sinergia 2017.
4. Susan L. Gearhart, Mesenteric Vascular insuficiency, Harisson Internal medicine. 18<sup>a</sup>: 2510-2513.
5. Van Home N, Jackson JP. Superior Mesenteric Artery Syndrome, StatPearls, 2020.
6. Ozkurt H, Cenker MM, Bas N, Ertuk SM. Measurement of the distance and angle between the aorta and the superior mesenteric artery. normal values in different BMI categories, 2007; 29: 595-9.
7. Almeida FS, Rocha D, Portuga IP. Acute mesenteric ischemia. 2018. <https://www.ncbi.nlm.nih.gov/pmc/articles/PMC6206376/> Insight Imaging.