

Synchronous Bilateral Breast Carcinoma: Case Report With Review

Goyal S*, Pujani M and Snigdha G

Department of Surgery, ESIC Medical College & Hospital, Faridabad, India

***Corresponding author:**

Sunder Goyal,
Department of Surgery, ESIC Medical College
& Hospital, Faridabad, India, E-mail: goyal.
sunder@yahoo.in

Received: 05 Mar 2021

Accepted: 24 Mar 2021

Published: 30 Mar 2021

Copyright:

©2021 Goyal S et al., This is an open access article distributed under the terms of the Creative Commons Attribution License, which permits unrestricted use, distribution, and build upon your work non-commercially.

Keywords:

Bilateral breast carcinoma; Synchronous breast carcinoma; Metachronous breast carcinoma; Infiltrating ductal carcinoma

Citation:

Goyal S. Synchronous Bilateral Breast Carcinoma: Case Report With Review. 2021; V1(4): 1-5.

1. Abstract

Bilateral Breast Carcinoma (BBC) is uncommon. Bilateral synchronous breast cancer accounts for 0.2-2% of all breast cancers. It is much less than metachronous bilateral breast carcinoma. It is called synchronous if another breast develops cancer within six months. If cancer in other breast develops with an interval of more than six months, it is named metachronous breast cancer. Moreover, BBCs are mostly lobular carcinomas, but here, we report a rare case of Infiltrating Ductal Carcinoma (IDC) affecting both breasts. Breast self-examination can aid in the early detection of mass in the contra lateral breast. Imaging screening can be done with the help of mammography and magnetic resonance imaging (MRI). MRI has greater sensitivity compared to mammography. As the incidence of BBC is less, so, there are no clear treatment guidelines. For proper treatment and better quality of life, early detection is essential.

2. Introduction

Breast cancer affects women all over the world. Carcinoma of the breast is usually unilateral but rarely can be bilateral. Due to better management and prognosis and increased life expectancy, an increasing number of women are at risk of developing bilateral breast carcinoma. It is called synchronous if another breast develops within six months and called metachronous breast cancer when the interval is more than six months. Bilateral Breast Carcinoma (BBC) is an uncommon presentation with an incidence of 2-5% of all breast malignancies. An increase in the detection of synchronous cancers has been reported following bilateral mam-

mography investigation of symptomatic breast disease and population-based breast screening. The risk factors connected with bilateral occurrence are familial or hereditary breast cancer, young age at primary breast cancer diagnosis, invasive lobular carcinoma, multicentricity and radiation exposure. Understanding the various factors contributing to the development of the contra lateral tumour is essential to evaluate and to do proper management of bilateral breast cancer.

3. Case Report

A 56-year-old female presented with a fungating growth in the left breast for five months which started as a small lump that gradually increased in size and involved the skin. There was no family history. Mass was an 8X6 cms in size and was present in the lower outer quadrant of left breast. Skin over the mass and nipple were involved. The mobile and firm lymph nodes were palpable in the anterior and central group of the left axilla. Another 4x4 cms firm lump with dimpling of the skin over mass was felt in the right breast in the lower outer quadrant, with no palpable axillary lymph nodes in the right axilla (Figure 1, 2).

Fine Needle Aspiration Cytology (FNAC) of the left breast revealed Infiltrating Ductal Carcinoma, and FNAC of the right breast lump also suggested Infiltrating Ductal Carcinoma (Figure 3). As a clinical examination, ultrasound abdomen, chest X-ray and PET scan whole body were normal, so there were no possibilities of distant metastasis. The patient underwent Modified Radical Mastectomy for left breast with axillary dissection and Simple Mastectomy for right breast in a single sitting. Histopathology of

both breasts specimen proved to be Infiltrating Ductal Carcinoma. Estrogen and Progesterone receptors were positive in resected tissue whereas negative for Her2neu receptor. The patient received six cycles of chemotherapy consisting of Cyclophosphamide, 5FU and Doxorubicin. Currently, she is on adjuvant hormonal therapy

with Tamoxifen with external beam Radiotherapy to both sides (Figure 4). Postoperatively patient recovered well. On follow-up, clinical examination and PET scan show no signs of recurrence after nine months.

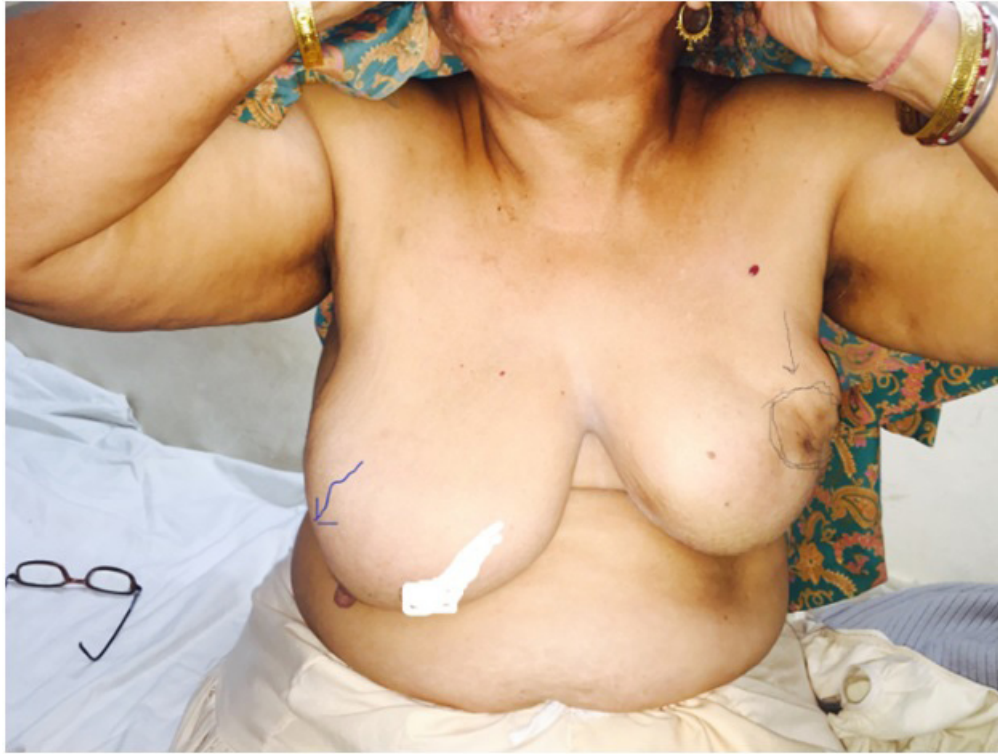

Figure 1: showing growth both breasts

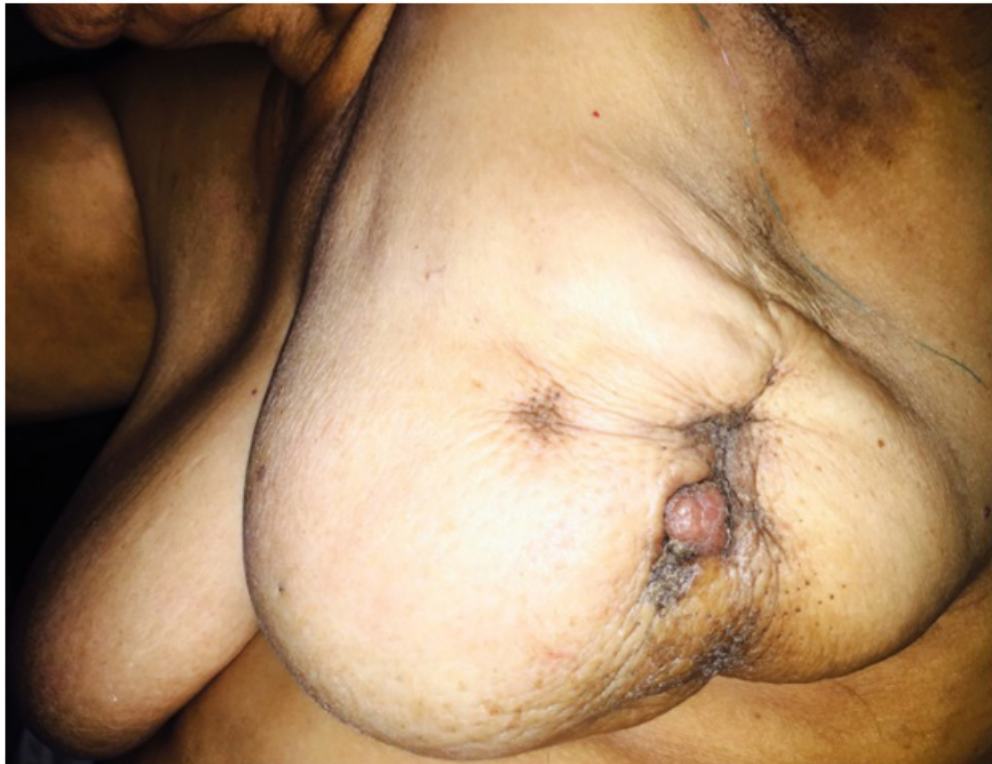

Figure 2: Ca Left Breast

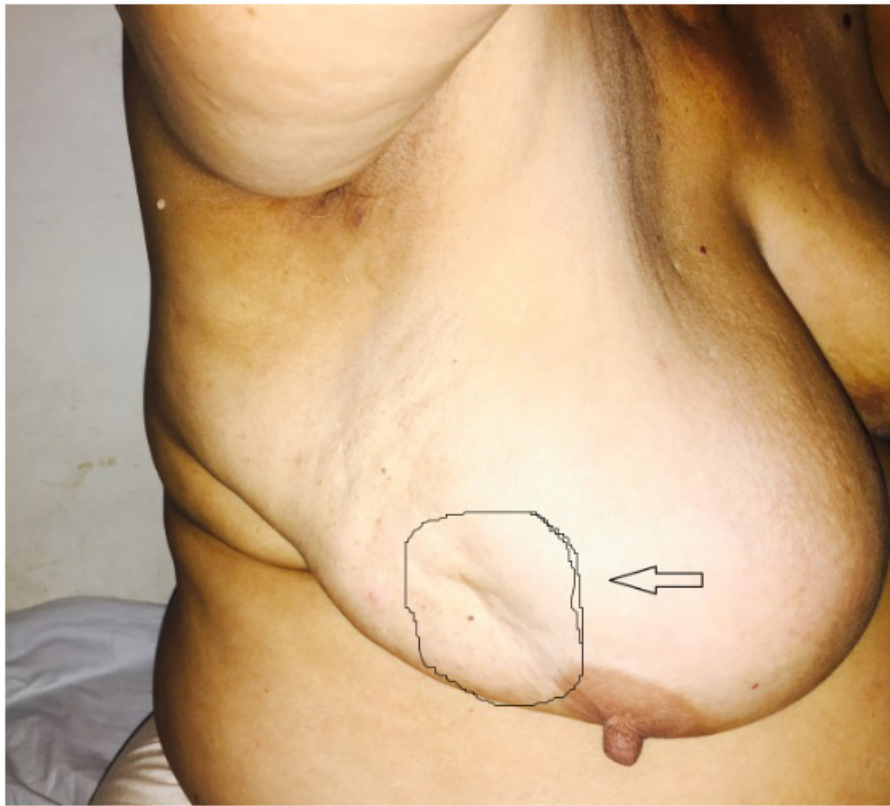

Figure 3: Ca Right Breast

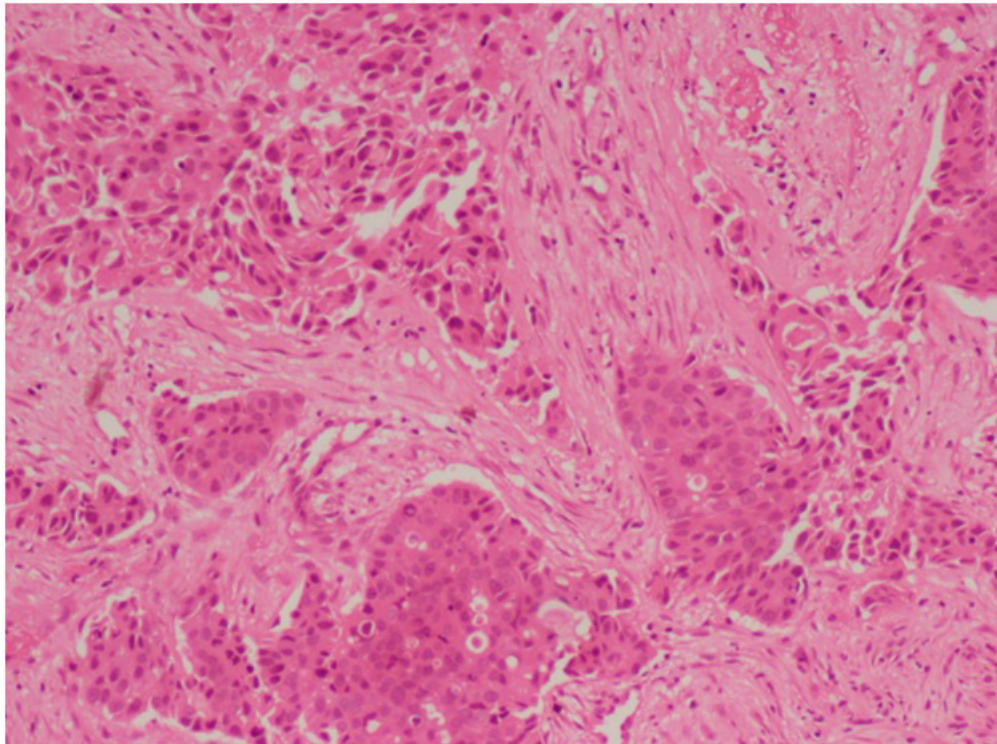


Figure 4

4. Discussion

The occurrence of bilateral breast carcinoma is uncommon. The majority of second primary breast cancer in the opposite breast is metachronous. However, they can be synchronous also. The incidence of bilateral synchronous breast cancer is about 0.2-2% of

all breast cancers. The use of bilateral mammography as a breast screening tool has increased the detection of synchronous cancers. The risk factors linked with bilateral occurrence are familial or hereditary breast cancer, young age at primary breast cancer diagnosis, invasive lobular carcinoma, multicentricity and radiation exposure [1, 4].

There are different opinion about the definition of synchronicity as a few scholars think that cancer in the second breast up to one year should be named as synchronous, where other thinks up to three months only. Thus, the incidence of primary synchronous bilateral breast carcinoma ranges from 0.3% to 12.2, [5-8] The exact aetiology is uncertain. [9] The various hypothesis suggesting risk factors for bilateral breast carcinomas are:

- lobular carcinoma as the primary carcinoma is an important factor
- Women with a previous history of breast cancer are at higher risk of developing contra lateral breast tumour with a two to six times greater relative risk than developing first breast cancer in general population. [10, 11]

Other factors include genetic predisposition and inadequate treatment received for the first tumour and nulliparity. [9,10] Chaudhary et al. 11 proposed criteria for the diagnosis of second primary breast cancer in 1984as follows

- there must be in situ change in the contra lateral tumour
- the tumour in both breasts should be different histologically
- the degree of histological differentiation of the tumour in the second breast must be distinctly more significant than that of the lesion in the first breast
- there must be no proof of local, regional, or distant metastases from cancer in the ipsilateral breast. [11]

Different morphological decisive factors like the presence of intraductal component, different histological variants, and different degrees of differentiation in bilateral tumours point to their origin as primary cancers. The in-situ component is the most crucial feature that excludes metastatic origin of bilateral breast tumours. [12] Various studies proposed guidelines, including Chaudhary et al. who proposed decisive factors to distinguish between a separate second primary and metastasis to the other breast. If there are no widespread systemic metastases, there are more chances of contra lateral breast tumours being separate primary tumours as in our case. [3,11,13,14] 5 to 10% of all breast cancers are hereditary, and women with BRCA mutations are at higher risk for bilateral breast cancer. In our case, family history was negative, so genetic testing was not done.15 Cavaliere A et al. reported that the frequency of invasive lobular carcinoma and lobular carcinoma in situ was higher in primary synchronous bilateral breast carcinoma in contrast to unilateral cancer. In our case, both tumours showed infiltrating ductal carcinoma within situ ductal component [16].

The multi-centric tumours are a risk factor for bilateral breast cancer. There are higher chances of positivity for ER and PR receptors, as in our case. It is a well-known fact that a previous history of breast cancer increases the risk of subsequent breast cancer in the contra lateral breast, between 0.5 to 0.80 per cent per year.

The prognosis is better in unilateral cancer breast than the bilateral breast. In the present case, the second lump in the right breast developed within three months after the left breast lump and was entirely ignored by the patient. As the prognosis of breast cancer depends upon the stage of cancer at the time of diagnosis, it is quite useful to do population screening that could perceive tumours before they spread locally, which might reduce mortality from breast cancer. Indeed, several studies have shown that breast screening by mammography in women over the age of 50 years will reduce cause-specific mortality by up to 30 per cent. Recent attention has been focused on using MRI for breast cancer screening in high-risk individuals and known BRCA mutation carriers [17].

MRI appears to be extra sensitive at detecting breast cancer in dense breast tissues in younger women. So, MRI of the breast is emerging as an essential tool in detecting, diagnosing, and staging breast cancer. It helps in evaluating the efficiency of chemotherapy and planning surgical treatment. Significantly, MRI helps in the detection of occult carcinomas both clinically and mammographically. Breast screening help in early diagnosis of breast cancer, which influences treatment and, hopefully, reduces mortality. The patient must be followed up for the rest of the life and the remaining breast's annual mammography [1].

In the literature, there are no proper treatment guidelines for bilateral breast cancer. Patients are often treated with bilateral mastectomy because the importance of conservative breast surgery is unclear [10]. Because of preventing bilaterality of tumours and various recent breast reconstruction options, there has been a dramatic increase in preference for prophylactic contralateral mastectomy for unilateral tumours [10].

Our management plan was based upon the grade of the individual tumours. The right breast had a Stage IV tumour. We, therefore, did modify radical mastectomy with a complete ipsilateral axillary dissection on the left side. In contrast, simple mastectomies because of a stage II tumour on the right side was adequate.

No clear relationship existed between ER and PR receptors positivity and bilaterality of the tumour. But bilaterality of breast tumours is more commonly seen in cases with Her-2/neu overexpression [10]. Studies suggest no significant difference in survival for patients with bilateral compared to unilateral tumour [18]. Mostly synchronous tumours were associated with lower survival in comparison to metachronous tumours [10].

5. Conclusion

An accurate diagnosis and appropriate management help improve longevity with an improved quality of life in bilateral synchronous breast cancer cases with different grades and histology.

References:

1. Ranjan A, Jaiswal P, Jha S. Synchronous bilateral invasive ductal carcinoma of the breast in a young female: a case report. National Journal of Medical and Allied Sciences. 2014; 3.

2. Dawson LA, Chow E, Goss P. Evolving perspectives in contralateral breast cancer. *European Journal of Cancer*.1998; 34: 2000-9.
3. Chandrika, Permi HS, Prasad HLK, Mohan R, Shetty KJ, Patil C, et al. Synchronous bilateral medullary carcinoma of the breast: Is it metastasis or second primary. *J Cancer Res Ther*. 2012; 8: 129-31.
4. Chuba PJ, Hamre MR, Yap J, Severson RK, Lucas D, Shamsa F, et al. Bilateral risk for subsequent breast cancer after lobular carcinoma-in-situ: analysis of surveillance, epidemiology, and results from data. *Journal of Clinical Oncology*. 2005; 23: 5534-41.
5. Kelmendi DUJ, Meiss RP. Primary synchronous bilateral breast cancer: Epidemiological approach. *Breast Cancer Res Treat*. 1988; 12: 311-4.
6. Dawson PJ, Maloney T, Gimotty P, Juneau P, Ownby H, Wolman SR, et al. Bilateral breast cancer: One disease or two?. *Breast Cancer Res Treat*. 1991; 19: 233-44.
7. Deo SV, Shridhar D, Purkayastha J, Bhutani M, Shukla NK, Raina V, et al. Therapeutic controversies in bilateral breast cancer. *Clin Oncol*. 2003; 15: 297-8.
8. Tulusan AH, Ronay G, Egger H, Willgeroth F. A contribution to the natural history of breast cancer. Bilateral primary breast cancer: Incidence, risks, and diagnosis of simultaneous primary cancer in the opposite breast. *Arch Gynecol* 1985; 237: 85-91.
9. Chen Y, Thompson W, Semenciw R, Mao Y. Epidemiology of contralateral breast cancer. *Cancer Epidemiol Biomarkers Prev*. 1999; 8: 855-61.
10. Kheirelseid EA, Jumustafa H, Miller N, Curran C, Sweeney K, Malone C, et al. Bilateral breast cancer: analysis of incidence, outcome, survival, and disease characteristics. *Breast Cancer Res Treat* 2011; 126: 131-40.
11. Chaudary MA, Millis RR, Hoskins EO, Halder M, Bulbrook RD, Cuzick J, et al. Bilateral primary breast cancer: a prospective study of disease incidence. *Br J Surg* 1984; 71: 711-4.
12. Intra M, Rotmensz N, Viale G, Mariani L, Bonanni B, Mastropasqua MG, et al. Clinicopathologic characteristics of 143 patients with synchronous bilateral invasive breast carcinomas treated in a single institution. *Cancer*. 2004; 101: 905-12.
13. Tuttle TM, Douglas Y. Bilateral Breast cancer. In: Singletary SE, Robb GL, Hortobagyi GN (eds) *Advanced Therapy of Breast disease*, 2nd edn. BC Decker Inc, USA. 2004; 629-630.
14. Leis HP. Bilateral breast cancer. *Surg Clin North Am*. 1978; 5: 833-41.
15. Krishnappa R, Chikaraddi SB, Deshmane V. Primary synchronous bilateral breast cancer *Breast cancer symposium*. 2014; 51: 256-58.
16. Cavaliere A, Bellezza G, Scheibel M, Vitali R, Sidoni A. Bio pathological profile of multiple synchronous homolateral and bilateral breast cancers. *Pathol Res Pract*. 2004; 200: 9-12.
17. Kriege M, Brekelmans CT, Boetes C, Besnard PE, Zonderland HM, Obdeijn IM, et al. Efficacy of MRI and mammography breast-cancer screening in women with a familial or genetic predisposition. *New England Journal of Medicine*. 2004; 351: 427-37.
18. Branica BV, Jezek SS, Juros Z, Meniga IN, Krizanac S. Synchronous bilateral breast carcinoma with two different morphology subtypes: A case report. *Coll Antropol*. 2010; 34: 701-4.